



**PATIENT**

Brexii Michalowskij

**SPECIES**

Canine

**BREED**

Bull Terrier

**SEX**

Female Spayed

**AGE**

6 years

**WEIGHT**

59.4lbs

**INTERPRETED BY**

Maggie Machen Lamy,  
DVM, DACVIM  
(Cardiology)

**IMAGING PERFORMED BY**

Potomac Mobile  
Veterinary Ultrasound

**HOSPITAL NAME**

Clarksburg Animal  
Hospital

**REFERRING VET**

Dr. Jarrett

**INVOICE**

29551

**DATE**

3/13/23

**PRESENTING CLINICAL SIGNS**

History: Recheck echo. Grade 3-4/6 heart murmur. BP: 130mmHg.  
-Pertinent previous echo findings (CVCA 2017): Mild SAS (<3m/s) with mild mitral valve dysplasia, secondary LVH, mild AI. Recommend Atenolol.

**ECHOCARDIOGRAM FINDINGS**

2D, m-mode, color flow and doppler imaging is available. The left ventricular wall is mild to moderately hypertrophied with a diffusely hyperechoic endocardium consistent with fibrosis. Mild papillary muscle hypertrophy. The left atrium is mildly enlarged. The right atrium is normal. The right ventricle appears normal. The mitral valve is thickened consistent with dysplasia. Mild to moderate MR. Elevated velocity. The tricuspid valve appears normal without TR. Blood flow through the LVOT is severely elevated and turbulent with a subaortic narrowing visualized (see below). SAM of the mitral valve is also appreciated with a fixed and dynamic profile appreciated. The aortic valve appears largely normal with a small aortic insufficiency. Normal RVOT velocity with no PI. No obvious shunts. No evidence of cardiac tumors or metastatic lesions on this scan. No pleural or pericardial effusion seen.

**CARDIAC CHART**

CANINE CARDIAC PARAMETERS	MR VMAX (m/s)	TR VMAX (m/s)	LA/AO (Boon method)	LA/AO (Heart Base; Swe)	FS (%)	EF (%)	EPSS (cm)	
NORMAL PARAMETER	4.5-5.5	<2.7	1.3	<1.6	28-40	40-100	<0.6	
PATIENT	6.9	2.0	1.3	1.4	35	65	NM	
CANINE CARDIAC PARAMETERS	HR (BPM)	AV VMAX (m/s)	PV MAX (m/s)	BODY WEIGHT (kg)	LA 2D short axis Base view (cm)	LVIDd Avg; 2D and m-mode short axis (cm)	LVIDs Avg; 2D and m-mode short axis (cm)	
NORMAL PARAMETER	50-100	0.7-1.7	0.7-1.6	BELOW	BELOW	BELOW	BELOW	
PATIENT	110	5.5	1.6	26.9	2.6	4.2	2.7	
*Normal chamber parameters expressed as a mean value (SD)								
<b>BODY WEIGHT DEPENDENT PARAMETERS</b>								
<i>*Note: All measurements based upon multi-modal images and methods. An average value is reported.</i>								
Adapted from June Boon, Veterinary Echocardiography, 1998 Rishniw M and Hollis NE, J Vet Intern Med 2000; 14:429-435 Hansson et al, Vet Rad and Ultrasound 2002 Bonagura et al. Echocardiography: principles of interpretation, Vet Clin North Am 15:1177, 1995					3	1.27 (5.3)	2.46 (2.46)	1.36 (5.5)
					5	1.40 (4.5)	2.74 (5.2)	1.60 (4.7)
					10	1.50 (3.8)	3.27 (3.5)	2.06 (3.1)
					15	1.83 (2.0)	3.71 (2.4)	2.43 (2.1)
					20	2.02 (1.9)	4.14 (2.2)	2.80 (2.0)
					25	2.18 (2.4)	4.48 (2.9)	3.10 (2.5)
					30	2.33 (3.3)	4.83 (3.9)	3.39 (3.4)
					35	2.48 (4.3)	5.17 (5.0)	3.69 (4.5)
					40	2.62 (5.2)	5.48 (6.1)	3.96 (5.4)
50	2.88 (7.1)	6.07 (8.3)	4.46 (7.4)					

**INTERPRETATION OF THE FINDINGS & FURTHER RECOMMENDATIONS**

The most significant finding is severe subaortic stenosis causing an increased flow velocity through the LVOT and aortic valve. There is mild to moderate LV hypertrophy present with significant endocardial fibrosis, which is concerning for development of arrhythmias. The LA is mildly dilated indicating low risk for imminent complication. There is also mitral valve dysplasia causing a mitral leak and systolic anterior motion of the anterior leaflet. This is further contributing to the outflow tract obstruction. No obvious additional defects are visualized.



**PATIENT**

Brexli Michalowskij

Compared to what is available from the prior report, there is evidence of progression as only a mild obstruction was noted in 2017.

**SPECIES**

Canine

Surgery for SAS has not been proven to alter long term outcome; however, select Universities will attempt a cutting balloon valvuloplasty. Continued medical management through heart rate control is recommended as below, in hopes of decreasing the degree of obstruction and pressure overload long term. Omega fatty acid supplementation and mild salt restriction may be of some long-term benefit.

**BREED**

Bull Terrier

Prognosis is guarded yet highly variable, with many dogs in the severe category succumbing to malignant arrhythmias by mid-life and others maintaining asymptomatic status for some time. Serial echocardiography is recommended lifelong to assess for progression and risk for complication as the animal matures. SAS can progress up to a year of age, which is of great concern in this case.

**SEX**

Female Spayed

**AGE**

6 years

Monitor for development of labored breathing, exercise intolerance or collapse episodes, as SAS patients are more predisposed to development of arrhythmias than to CHF. Mild exercise restriction is advised.

**WEIGHT**

59.4lbs

Anesthetic risk is moderately elevated. Cardiac protective drug choices (opioid/benzodiazepine premedication, propofol or alfaxalone induction, isoflurane gas) are recommended. Pre-oxygenate for 5-10 minutes prior to induction. Avoid heart rate stimulating drugs such as atropine or glycopyrrolate unless clinically indicated. Avoid ketamine and acepromazine due to systemic vascular effects. Monitor for arrhythmias, hypotension, and hypoxia both intra and post-operatively and intervene as necessary. Mild IV fluid restriction is advised. Recommend prophylactic antibiotics for any orthopedic or dental procedure in the future given predisposition to endocarditis.

**INTERPRETED BY**

Maggie Machen Lamy,  
DVM, DACVIM  
(Cardiology)

**PLAN**

Consider referral to a local Cardiologist in this case if elected. If declined, continue Atenolol to effect: 0.5-1.5mg/kg SID-BID maintaining a stressed heart rate of <130bpm.

**IMAGING PERFORMED BY**

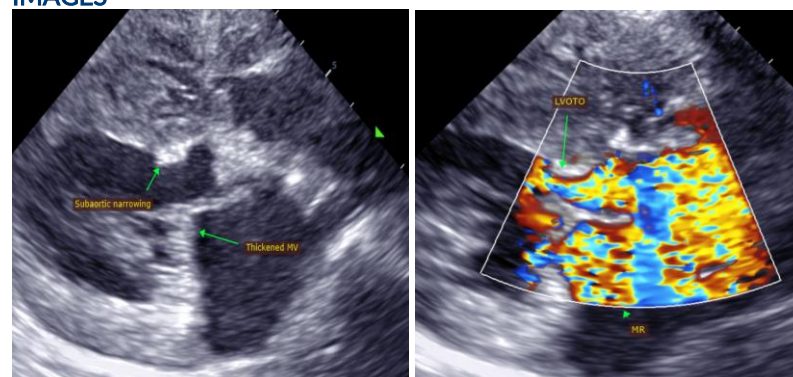
Potomac Mobile  
Veterinary Ultrasound

Recommend recheck echocardiogram in 1 year to screen for progression.

**IMAGES**

**HOSPITAL NAME**

Clarksburg Animal  
Hospital



**REFERRING VET**

Dr. Jarrett

**INVOICE**

29551

**DATE**

3/13/23



**PATIENT**

Brexli Michalowskij

**SPECIES**

Canine

**BREED**

Bull Terrier

**SEX**

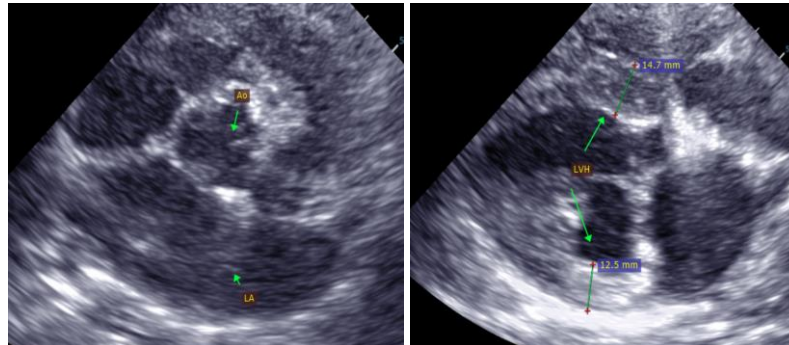
Female Spayed

**AGE**

6 years

**WEIGHT**

59.4lbs



The information and recommendations provided are based on the images presented by the referring veterinarian. No evaluation can be communicated regarding pathology that was not visible in the image/video clips provided.

Thank you for this referral. This report was generated using transcription software, and minor dictation errors may be present. If the clinical or image interpretation does not parallel your findings or if I can be of any further assistance, please contact me.

Maggie Machen Lamy, DVM  
Diplomate of the American College of Veterinary Internal Medicine (Cardiology)  
info@sonopath.com

**INTERPRETED BY**

Maggie Machen Lamy,  
DVM, DACVIM  
(Cardiology)

**IMAGING PERFORMED BY**

Potomac Mobile  
Veterinary Ultrasound

**HOSPITAL NAME**

Clarksburg Animal  
Hospital

**REFERRING VET**

Dr. Jarrett

**INVOICE**

29551

**DATE**

3/13/23